

Cheiloscopy As a Means of Personal Identification in Forensic Dentistry: A Study

Abstract

Introduction: As dental surgeon has to be actively involved in various objectives of forensic odontology, his role in personal identification and criminal investigation is very much important as his evidence would be very much useful in law and justice. **AIM:** The aim of this study was to determine the distribution of the various patterns of lip prints in adult subjects of both genders and detect if any specific pattern is present in majority of the subjects. **Materials and Methods:** This study consists of 100 randomly selected subjects comprising 50 males and 50 females with age ranging from 18 to 24 years. Study sample was derived from different dental hospital. **Results & Conclusion:** Most common lip print patterns were found to be Type I and Type II. Most common lip print pattern amongst males was found to be Type I. Most common lip print pattern amongst females was found to be Type II.

Key Words

Lip prints; forensic; human identification

Biswaroop Mohanty¹, Ashwani kumar Jadon², Saurabh Rathore³, Preeti Bhatt⁴, Sandeep Gupta⁵, Shivali Vaid⁶

¹Assistant Professor, Department of Orthodontics and Dentofacial Orthopedics, Kalinga Institute of Dental Sciences, Bhubaneswar, Odisha, India

²Assistant Professor, Department of Orthodontics & Dentofacial Orthopaedics, Maharana Pratap College of Dentistry & Research Center, Gwalior, Madhya Pradesh, India

³Assistant Professor, Department of Orthodontics & Dentofacial Orthopaedics, Maharana Pratap College of Dentistry & Research Center, Gwalior, Madhya Pradesh, India

⁴Assistant Professor, Department of Prosthodontics, Hitkarni Dental College, Jabalpur, Madhya Pradesh, India

⁵Reader, Department of Conservative Dentistry, Maharana Pratap College of Dentistry & Research Centre, Gwalior, Madhya Pradesh, India

⁶Reader, Department of Oral Pathology, Maharana Pratap College of Dentistry & Research Centre, Gwalior, Madhya Pradesh, India

INTRODUCTION

There are numerous methods of human identification which are well documented and established. One of the most interesting emerging methods of human identification which originates from the criminal and forensic practice is human lips recognition. The wrinkles and grooves on labial mucosa, called as sulci-labiorum forms a characteristic pattern and the study of which is referred to as cheiloscopy. The external surface of lip has numerous elevations and depressions that form a characteristic pattern, referred to as lip prints, lip prints can be obtained at the crime scene from clothing, cups, glasses, cigarettes, windows and doors.^[1] Lip prints are unique and do not change during the life of a person.^[2,3] As dental surgeon has to be actively involved in various objectives of forensic odontology, his role in personal identification and criminal investigation is

very much important as his evidence would be very much useful in law and justice.^[4]

Historical Background

The biological phenomenon of systems of furrows on the red part of human lips was first noted by anthropologists, R. Fischer was the first to describe it in 1902.^[5] Use of lip prints in personal identification was first recommended in France by Edmond Locard.^[6] Santos was the first person to classify lip grooves in 1967,^[7] and divided them in to four types namely:

1. Straight line
2. Curved line
3. Angled line
4. Sine-shaped line

Suzuki and Tsushihashi^[8] introduced their classification into 6 Types .

- Type I is a longitudinal grooves running through the whole width of the lip.

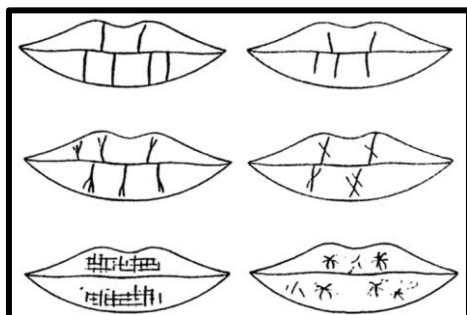


Fig. 1

- Type I' is partial longitudinal grooves.
- Type II is branched grooves.
- Type III is intersected grooves,
- Type IV is reticular grooves and
- Type V is undifferentiated grooves.

Type I: Complete straight grooves. **Type I':** Partial straight grooves. **Type II:** Branched grooves. **Type III:** Intersected grooves. **Type IV:** Reticular grooves. **Type V:** Undifferentiated grooves (Fig. 1). A study by Sonal-Nayak states, Type I and Type I' patterns were found to be dominant in females, while Type III and Type IV patterns dominant in males.^[9] Sivapathasundharam, Ajay and Sivakumar in 2001 studied the incidence of particular lip print patterns in the Indo-Dravidian population and found that Type III was predominant.^[10] For the purpose of determination of the sex of the person from lip prints, Gondivkar SM *et al.*, in 2009 have studied 70 each male and female subjects in Maharashtra and were able to predict the sex with a high degree of accuracy.^[11] In another study conducted by Vahanwala-Parekh, it was shown that all four quadrants having same type were predominantly seen in female subjects and male subjects showed presence of different patterns in a single individual.^[12]

Aim of the Work

The aim of this study was to determine the distribution of the various patterns of lip prints in adult subjects of both genders and detect if any specific pattern is present in majority of the subjects.

MATERIALS AND METHODS

Study Sample

This study consists of 100 randomly selected subjects comprising 50 males and 50 females with age ranging from 18 to 24 years. Study sample was derived from different dental hospital. Careful examination was conducted during selection of subjects to eliminate those individuals who had developmental, morphological and pathological conditions of lip. The procedure was explained to

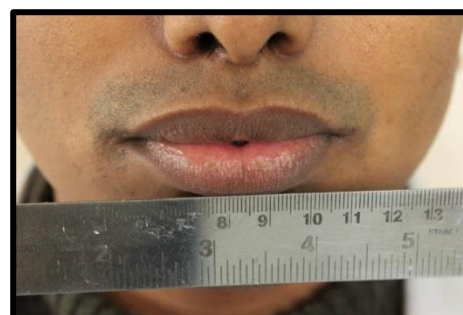

Fig. 2

the subjects & his/her consent was taken. The subjects were asked to clean his/her lips with water & dry them with tissue paper.

Study Materials and Technique

Lip prints were recorded by direct photography of the lips using a digital SLR camera with macro lens and ring flash. A scale divided into centimeters was fixed to the inferior border of the lower lip for groove counting/cm.^[13] The images obtained were analyzed using an image viewing software on a computer. In the present study, the type of lip print was recorded in upper and lower lip for comparison and finalization using the classification system advocated by Suzuki and Tsushihashi.^[8]

RESULTS

Observation

The study of lip print pattern of 50 males and 50 females revealed the following observations: It is recorded that in males 34.96% were having Type I, 17.52% with Type I', 28.04% with Type II, 12.48% with Type III, 2.62% with Type IV and 4.38% with Type V lip prints. In females 24.65% were having Type I, 20.35% with Type I', 30.46% with Type II, 16.54% with Type III, 1.25% with Type IV and 6.75% with Type V lip prints. In both males and females 29.82% were having Type I, 18.93% with Type I', 29.25% with Type II, 14.51% with Type III, 1.93% with Type IV and 5.56% with Type V lip prints (Table 1).

1. No two lip prints matched with each other, thus establishing the uniqueness of the lip prints.
2. Type II was most commonly seen in females, whereas Type I was seen most commonly in males.
3. Type IV was found to be the least common lip pattern in both males and females.

DISCUSSION

Lip prints are very useful in forensic investigation and personal identification. They are considered to be most important forms of transfer evidence, and are analogous to finger prints. Lip prints are usually left at crime scenes and can provide a direct link to

the suspect In the past, some researchers have worked on lip prints. Also, the use of lipsticks is not indispensable for leaving lip prints. The edges of the lips have sebaceous glands, with sweat glands in between. Thus, secretions of oil and moisture from these enable development of latent lip-prints, analogous to latent finger prints.^[14]

Table 1

Lip-pattern	Male (%)	Female (%)	Mean (%)
Type I	34.96	24.65	29.82
Type I'	17.52	20.35	18.93
Type II	28.04	30.46	29.25
Type III	12.48	16.54	14.51
Type IV	2.62	1.25	1.93
Type V	4.38	6.75	5.56

Lip prints are characterized by their permanence and are, therefore, referred to as persistent lip-prints. Although invisible, these prints can be lifted using materials as aluminum powder and magnetic powder.^[15,16] Although many systems of classification of lip print patterns have been proposed, the classification by Suzuki and Tsuchihashi^[8] is most widely accepted. The same system of classification was used in our study. According to the results of the present study Type I and Type II were the most common types of lip print pattern which is in concordance with the results of the study by Randhwa *et al.*^[17] Type I was the most common pattern seen in the males this in contrast to results of the study by Randhwa *et al.*,^[17] and Sonal-Nayak^[9] which showed that the most common pattern was Type III. Our study showed that the most common pattern amongst females was Type II. This again was in contrast to the studies by Randhwa *et al.*,^[17] and Sonal-Nayak.^[9] Least common pattern was found to be Type IV.

CONCLUSION

1. Most common lip print patterns were found to be Type I and Type II.
2. Most common lip print pattern amongst males was found to be Type I.
3. Most common lip print pattern amongst females was found to be Type II.
4. No two lip print patterns were found to be same.
5. Lip print identification can be reliably used as a means of personal identification.

REFERENCES

1. Einstein AK, Sivapathasundharam B, Saraswathi TR. Limitations in forensic Odontology. *J Of Forensic Odontology* 2009;1:8-10.
2. Williams TR. Lip prints - Another means of identification. *J Forensic Ident* 1991;41(3):190-4.
3. Tsuchihashi Y. Studies on personal identification by means of lip prints. *Forensic Sci* 1974;3:233-48.
4. Shamim T, Varughese I, Shameena, Sudha S. Forensic odontology - a new perspective. *Medico legal update* 2006;6(1):1-4.
5. Kasprzak J. Possibilities of cheiloscopy. *Forensic Sci Int* 1990;46:145-51.
6. Thomas CJ, van Wyk CW. The palatal rugae in identification. *J Forensic Odontostomatol* 1988;6:21-7.
7. Santos M. Queiloscopy: A supplementary stomatological means of identification, *International Microform J Legal Medicine* 1967:2.
8. Suzuki K, Tsuchihashi Y. A trial of personal identification by means of lips print. *Jap J Leg Med* 1969;23:324-5.
9. Vahanwala S, Nayak CD, Pagare SS. Study of lip prints as aid for sex determination. *Medico -Legal Update* 2005;5:93-8.
10. Sivapathasundharam B, Prakash PA, Sivakumar G. Lip Prints (Cheiloscopy). *Indian J Dent Res* 2001;12(4):234-7.
11. Gondivkar SM. Chelioscopy for sex determination. *Journal of Forensic Dental Sciences* 2009;1:56-60.
12. Vahanwahal SP, Parekh DK. Study of lip prints as an aid to forensic methodology. *J Indian Dent Assoc* 2000;71:269-71.
13. Saad WM, Kamel AH, Hassan FZ, El-Otiefy MA. Genetic Studies on the Inheritance of Lip Prints in-CleftLip and Palate Egypt. *J Plast Reconstr Surg* 2005;29(1):9-12.
14. Ball J. The current status of lip prints and their use for identification. *J Forensic Odontostomatol* 2002;20:43-6.
15. Castelló A, Seguí AM, Verdú F. Luminous lip prints as criminal evidence. *Forensic Sci Int* 2005;155:185-7.
16. Segui MA, Feucht MM, Ponce AC, Pascual FAV. Persistent lip sticks and their prints: New hidden evidence at the crime scene. *Forensic Sci Int* 2000;112:41-7.
17. Randhawa K, Narang RS, Arora PC. Study of the effect of age changes on lip print pattern and its reliability in sex determination. *J Forensic Odontostomatol* 2011;29:2:45-51.